

Diode laser treatment for osteal and osteoarticular panaritium

Valery A. Privalov, Ivan V. Krochek, Alexander V. Lappa*,
Andrew N. Poltavsky, Andrew A. Antonov
Medical Physics Center
at Chelyabinsk State University and Chelyabinsk State Medical Academy
Br. Kashirinykh 129, Chelyabinsk, 454021, Russia

ABSTRACT

Laser osteoperforation method, initially developed for treatment of osteomyelitis, was successfully applied to 66 patients with osteal and osteoarticular panaritium. The procedure consisted in perforation of the affected phalanx with diode laser radiation (wavelength 970nm; average power 10-12W; pulse mode 100/50 ms), delivered through quartz monofiber. Additional laser induced thermotherapy (power 2-3W; continuous mode) was fulfilled for persistent fistulas. In comparison with conventional surgery, laser osteoperforation provided faster pain relieve, edema dissipation, wound and fistula closure; good functional results; decreasing of disability cases number.

Key words: diode laser, osteoperforation, panaritium, osteomyelitis, infra-red irradiation, LITT

1. INTRODUCTION

The number of acute purulent diseases of hand and fingers is 15-30 % of all outpatient surgery, and 64-66 % of purulent diseases. Panaritium is annually revealed in 0.5-1.3 % of the population of Russia. So, the treatment of osteal and osteoarticular forms of panaritium (14.4 % of all patients with purulent diseases of hand) is a complex and actual problem.

Though appreciable progress in surgery development has been achieved, the only efficient method of treatment of osteal and osteoarticular panaritium is the excision of necrotized soft tissue and bone sequestrs (necrsequestrectomy). This method, despite of long experience of use and reliable results, has a lot of disadvantages. Radical necrsequestrectomy quite often results in truncation of a segment of phalanx; and treatment of the articular panaritium quite often leads to the ankylosis of the joint, that causes appreciable disability in some patients. Treatment of these patients is rather expensive and time-consuming.

The aim of our study is to develop and introduce a new mini-invasive method of treatment of osteal and osteoarticular panaritium with the help of high-intensive diode laser to improve anatomic and functional results of treatment in this patients.

2. METHODOLOGY

In 2000 – 2004, we examined and treated 127 patients, aged 6 to 72, with osteal and osteoarticular panaritium of different localization. To compare the suggested and traditional methods of treatment, two representative groups of patients were selected in random manner: the basic group and group of comparison. The basic group consisted of 66 patients with osteal and osteoarticular panaritium, who were treated with application of high-intensive diode laser. The group of comparison consisted of 61 patients, who were treated with traditional surgical methods. Age distribution of patients is presented in Table 1. Distribution of patients by form of disease is presented in Table 2.

Osteal or osteoarticular panaritium was identified by the typical clinical findings: pain syndrome in the affected phalanx or joint, positive symptom of axial load, restriction of movement, morbidity at active and passive motions in the affected joint for osteoarticular panaritium. Laboratory researches didn't reveal any essential deviations.

*lappa@csu.ru

Roentgenologic signs of osteal and osteoarticular panaritium were the focuses of destruction or expressed osteoporosis of the phalanx for osteal panaritium; narrowing and deformation of joint space, and destruction of articular surfaces for osteoarticular panaritium. Roentgenologic examinations were carried out before surgery and 1, 3, 6, 12, 24 months after it.

Table 1. Age distribution of patients.

Age	Basic group		Group of comparison	
	Number	Percentage	Number	Percentage
6-14 years	27	40.9%	30	49.2%
15-19 years	8	12.1%	6	9.8%
20-65 years	30	45.5%	21	34.4%
Over 65 years	1	1.5%	4	6.6%
Total	66	100%	61	100%

Table 2. Forms of disease

	Basic group		Group of comparison	
	osteal panaritium	osteoarticular panaritium	osteal panaritium	osteoarticular panaritium
Number of patients	47	19	47	14

For the objective evaluation of wound healing process, we analyzed:

- duration of pain syndrome and edema of soft tissues, wound discharge nature, and the period of wound healing;
- results of bacteriological analyses, carried out before operation, 2-3 and 5-7 day after it;
- results of cytological researches on 1-3, 5 and 7 day. Presence of tissue detritus, variety and quantity of microorganisms, undergone phagocytosis, were determined with microscopy. The time of transfer from degenerative-inflammatory cytological picture to inflammatory-regenerative type was estimated.

2.1 Methods of treatment

Experimentally developed method of laser osteoperforation²⁻⁷, was applied to the patients of the basic group. Diode laser LS-0.97-IRE POLUS (Russia), with maximum power 30 W and 970 nm wavelength, was used for the operation. Laser beam was delivered to the object by 400 µm monofiber with heat-resistant cover.

2.2 Operation technique

Operation was carried out under intravenous or conduction anaesthesia in aseptic conditions. 2-4 transcutaneous laser osteoperforation holes were made in the area of bone destruction determined with roentgenography. Pulse mode, 100/50 ms (pulse/pause duration), with 16 W peak power was used. For children, lower power (7-10 W) was used for osteoperforation, because of lower bone density. Duration of osteoperforation was 2-4 s. The holes were made in two perpendicular planes. If there was a fistula, laser induced thermotherapy (LITT) was performed in continuous mode (2-3 W power, duration up to 15 s). During LITT the light guide was gradually moved along the fistula tract. After operation a dry sterile dressing or antiseptic was applied. Drainage of the fistula was not used. Antibiotics were not administered in the postoperative period. (It was not required.)

The traditional surgery included:

- Radical and economical excision of the purulent-necrotic focus (necrsequestrectomy).
- Drainage in different ways or oversewing of the wound.
- Immobilization.
- General and local antibacterial therapy.

Nearest results of osteal and osteoarticular panaritium treatment were assessed by:

- Duration of pain syndrome after operation.
- Time of edema dissipation.
- Duration of the wound (fistula) repair.
- Time of transfer from degenerative-inflammatory cytological picture to inflammatory-regenerative type
- Hospitalization period (and period of follow-up care).
- Period of disability after discharge from the hospital.

Long-term results were estimated in 3, 6, 12 months by roentgenography and functional criteria. They were considered as good, satisfactory and unsatisfactory.

Good results. The patient maintains the professional working capacity. Complete or almost complete recovery of finger function (reduction of motion volume is no more than 25 % in comparison with the similar finger of the healthy hand, grip function of the hand is completely preserved, reduction of the finger strength is no more than 15 %).

Satisfactory results. The patient does the same kind of work, but there is a reduction of working capacity. (reduction of motion volume by 25-50 %, disorder of some kinds of grip, reduction of finger strength is more than 25 %).

Unsatisfactory results. Drastic reduction of working capacity or disability, bony or fibrous ankylosis of the joint, basic kinds of grip are lost. Mutilating operations (amputation, exarticulation of the finger, excision of flexor tendon, etc.) were carried out.

3. RESULTS AND DISCUSSION.

Results are presented in tables 3-8, statistical error of all numbers does not exceed 10% with confidence 0.95. Time of pain syndrome relieve and local edema dissipation are presented in Table 3

Table 3. Time of pain syndrome relieve and local edema dissipation after operation (days)

	Basic group	Group of comparison
	66 patients	61 patients
Pain syndrome	0.7	2.8
Edema	0.8	2.4

As follows from Table 3, the pain syndrome and edema were completely removed within the first day after operation in the basic group of patients, while in the patients of the control group the pain syndrome and edema usually remained for three days after operation. So, this period for the basic group was significantly less then for the group of comparison.

Period of wound or fistula repair was also essentially different for the two groups of patients. We observed that duration of wound repair in both groups depended directly on the dimension of the wound after the excision (necrectomy), and if there had been initial fistula, the period of its repair substantially depended on the method used for treatment. Therefore, the time of fistula repair and time of wound repair after panaritium drainage and previous operations were estimated separately. Cytological picture was estimated for wounds.

In patients from basic group with acute stage of disease, who hadn't had surgery earlier, we drained the panaritium and excised the devitalized tissues, if any. Sequestrectomy was not carried out in this group of patients, laser osteoperforation of the bone was fulfilled according to accepted method. In the control group routine sequestrectomy was carried out, with open method of wound management after operation. Daily cytological researches were used for estimation of the time of transfer from degenerative-inflammatory cytological profile to inflammatory-regenerative type. Thus, we received the following results (Table 4.).

Table 4. Time of fistula repair and change of the type of cytological picture (days)

	Basic group	Group of Comparison
	42 patients	40 patients
Fistula repair	1.4	5.3
	26 patients	21 patients
Change of cytological profile	3.1	6.5

Referring to Table 4, the manifestations of inflammation in the basic group of patients calm down within 2-3 days and in control group within 5-6 days. These results show faster transition of inflammation phase to regeneration phase after high-intensive laser treatment in comparison with traditional necrsequestrectomy. We failed to compare cytological picture of wound discharge from fistula after surgery because of the short terms of fistula repair after laser osteoperforation, which made the dynamic study of discharge impossible. After laser treatment the fistula usually closed within 1-2 days, while after excision of sequester the discharge from fistula lasted over 4-5 day (Tables 5 and 6).

Table 5. Duration of inpatient treatment and period of disability for osteal panaritium (days)

	Basic group	Group of comparison
	47 patients	47 patients
Inpatient treatment	3.4	7.3
Disability after discharge from hospital	7.4	14.0

Table 6. Duration of inpatient treatment and period of disability for osteoarticular panaritium (days)

	Basic group 19 patients	Group of comparison 14 patients
Inpatient treatment	4.2	12.1
Disability after discharge from hospital	10.8	17.6

Tables 5 and 6 show, that there is a reliable decrease of inpatient treatment duration in the basic group, for 4 days on the average for osteal, and for 8 days for osteoarticular panaritium. Furthermore, the patients of the basic group were discharged with the wound almost closed up, and did not require the subsequent out-patient dressings, that improved their psychological state and considerably facilitated the rehabilitation period. In addition, antibiotics were not prescribed to the patients of the basic group, and their intramuscular introduction is often uneasy for patients, causing painful post-injection infiltrates and other specific complications. Patients of control group, as a rule, were discharged for the out-patient treatment after wound cleansing and purulent discharge stopping. They required out-patient treatment and dressings, and so the disability period after operation became longer. The rehabilitation period of patients of control group was also complicated by the consequences of antibiotic administration, such as a dysbacteriosis and post-injection infiltrates. Reduction of rehabilitation period for osteoarticular panaritium in basic group was also promoted by the opportunity of earlier beginning of therapeutic exercises and mechanotherapy.

Unfortunately, laser osteoperforation didn't lead to recovery in 2 patients (4 %) of basic group. In one case the parameters of osteoperforation were not adhered, in the other there was an extensive area of destruction. Thus it was necessary to resort to the traditional necrsequestrectomy. 67.7 % of the patients of control group were operated once more (on an outpatient or inpatient basis). The conditions of each reoperation were much worse because of purulent fistulas,

additional wounds and cicatricial deformation of soft tissues. This circumstances had an adverse effect on the subsequent wound repair and anatomic-functional results of treatment.

Long-term functional results of laser osteoperforation and traditional method of treatment are presented in Tables 7 and 8.

Table 7. Long-term results of treatment of osteal panaritium

	Basic group (47 patients)		Group of comparison (47 patients)	
Good results	45	95.7%	40	85.1%
Satisfactory results	2	4.3%	6	12.8%
Unsatisfactory results	0	0%	1	2.1%
Total	47	100%	47	100%

Table 8. Long-term results of treatment of osteoarticular panaritium

	Basic group (19 patients)		Group of comparison (14 patients)	
Good results	12	63.2%	3	21.4%
Satisfactory results	5	26.3%	7	50%
Unsatisfactory results	2	10.5%	4	28.6%
Total	19	100%	14	100%

Analysis of roentgenologic data showed the advantages of laser osteoperforation. When there had been small bone sequestrs before operation, they were not found at the roentgenologic control even in the nearest postoperative period (1-2 months) after laser osteoperforation.

When the initial roentgenograph showed the bone destruction with defect of the phalanx, the complete regeneration of bone structure of the affected phalanx was observed after laser osteoperforation. (Fig. 1).

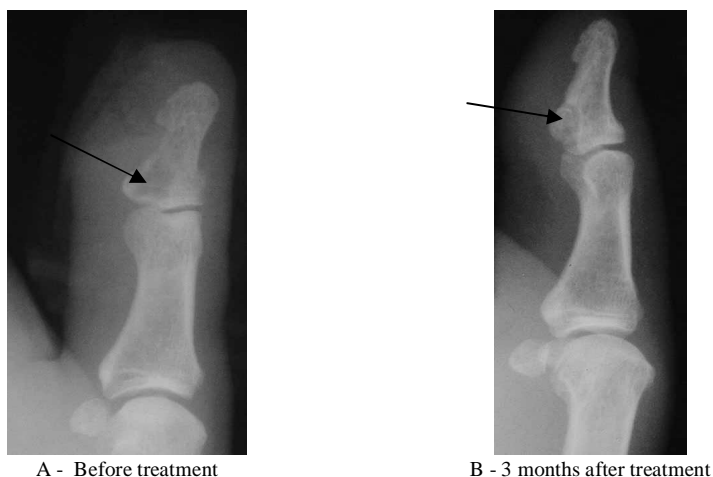


Fig. 1. Change of roentgenologic picture of osteal panaritium in the patient X., 47 y.o.
 A- focus of destruction (marked by arrow) in the base of distal phalanx, swelling of soft tissues.
 B - complete regeneration of distal phalanx structure.

In patients with osteoarticular panaritium, laser osteoperforation facilitated fast regeneration of the bone structures, forming the joint, and also partial or complete regeneration of joint space (Fig. 2.).

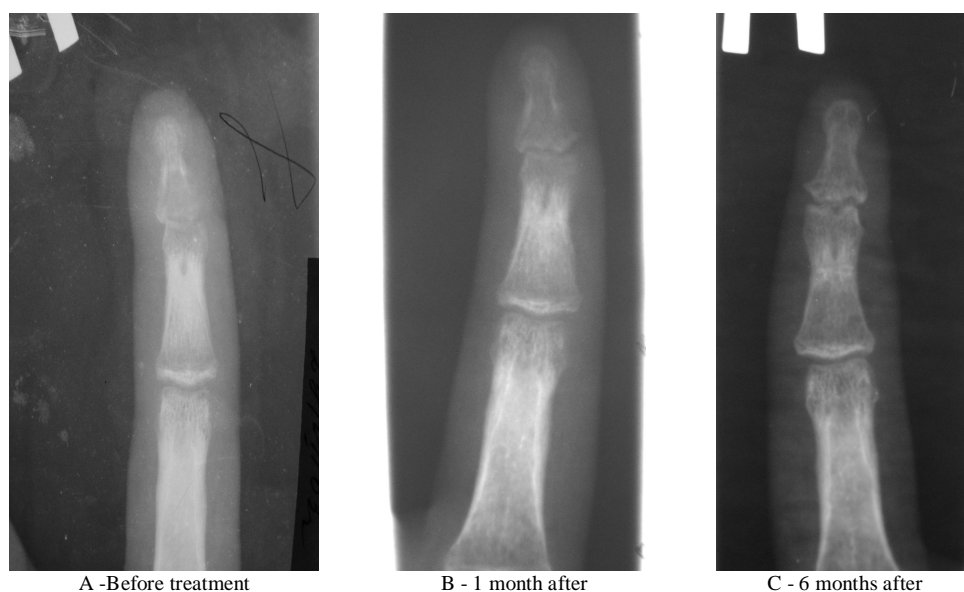

Fig. 2. Roentgenographs of patient L, 14 y.o., with osteoarticular panaritium.

A - Destruction and rarefaction of bone structure of the head of middle and base of distal phalanges, narrowing and deformation of joint space.

B - Osteoporosis of the head of middle and base of distal phalanges, narrowing of joint space.

C - Complete regeneration of bone structure of phalanges, insignificant deformation of joint space.

In the remote period after osteoperforation, the area of bone destruction was replaced by osteosclerosis area, that is evidence of stopping of purulent inflammatory process in the bone. Recurrences of destructive and of purulent inflammatory process were not marked during the observation period (3 years).

Analysis of roentgenologic changes after traditional necrosectomy often revealed the absence of a fragment of bone phalanx. If a sufficient amount of soft tissue was left and small volume of bone was excised, the bone regeneration was observed in some cases from 3 months to 2 years since operation. However the regeneration of bone phalanx was not complete in all cases. Sometimes faulty regeneration of bone structure after sequestrectomy was marked, that considerably affected the functional capacity of the finger. For osteoarticular panaritium the stiffness or ankylosis of the joint were observed in the remote period. This circumstances considerably affected the appearance and function of the finger. So, the regeneration of bone tissue of the phalanx after operative treatment was usually incomplete, in contrast to the patients of the basic group, where the bone was not removed and regenerated well.

The question of necessary number of osteoperforation holes and distance between them deserves special attention. This method had initially been developed in Chelyabinsk Medical Academy for treatment of experimental acute purulent osteomyelitis in rabbits². As the experimental results were good, the method was applied for treatment of acute hematogenic osteomyelitis in 16 children^{1,3-5} and various forms of a chronic osteomyelitis in 75 adult patients^{1,3-5}. Positive effect of high-intensive laser radiation on the angiogenesis and bone regeneration^{1,3-5} was observed. Besides, the potent bactericidal effect of laser osteoperforation, resulting in fast sanitation of bone lumen^{1,3-5} was marked. Studies of temperature fields in tissues with preserved blood flow showed², that laser radiation with power up to 30 W and exposure time up to 10 s did not cause the deep thermal damage of soft tissues and bones. While development of this procedure, we have found out, that if the osteoperforation holes were formed too close to each other, it caused thermal lesion of big area of the phalanx bone with its subsequent assimilation. So, we came to the conclusion, that the distance between perforation holes should be more than 5 mm to avoid undesirable thermal damage of the bone. If the additional osteoperforation holes are necessary, they should be made in two perpendicular planes. This arrangement of osteoperforation holes does not cause any undesirable consequences. It is necessary to note, that the density of bone

tissue greatly depends on age of the patient: the elder is the patient; the higher is the bone density. Therefore the laser power for osteoperforation in children should be reduced to 7-10 W, and in mature and aged patients the greater power should be used (up to 10-15 W) ^{1,3-6}.

For persistent fistula, lined with pathological granulation tissue, which in itself can sustain the inflammation and existence of the fistula, laser induced thermotherapy of the fistulous tract with subablation parameters of laser radiation is expedient^{6,7}. For osteal and osteoarticular panaritium we determined the optimum parameters of interstitial thermotherapy for fistula: laser power 2-3 W, constant mode, exposition up to 15 s. We achieved the even tissue coagulation without undesirable local overheat of tissues, moving the end of light guide along the full length of the fistula tract during laser induced thermotherapy ³⁻⁶.

4. CONCLUSION

So, our clinical experience of laser osteoperforation for treatment of osteal and osteoarticular panaritium proved the efficiency of this method. In comparison with the traditional method, it is less traumatic, provides marked sanitation effect, causes pathogen death, that promotes fast elimination of inflammation focus, improves microcirculation and bone tissue regeneration.

REFERENCES

1. I.V. Krochek, V.A. Privalov, A.V. Lappa, S.V. Nikitin. "The clinical-morphological estimation of the results of laser osteoperforation in treatment of chronic osteomyelitis," *Vestn. Khir. Im. II Grek.* **163(6)**, 68-72, 2004. (in Russian)
2. V.A.Privalov, A.L.Svetlakov, O.S.Kuchakovsky, A.V.Lappa, A.A.Kazakov, A.I.Kozel "Hyperthermal effect of laser osteoperforation in treatment acute purulent osteomyelitis", in *Thermal Therapy, Laser Welding, and Tissue Interaction*, S. G. Bown et al., eds, Proc. SPIE 3565, 72-79, 1998.
3. V.A.Privalov, I.V. Krochek, A.V. Lappa "Diode laser osteoperforation and its application to osteomyelitis treatment", in *Laser-Tissue Interactions, Therapeutic Applications, and Photodynamic Therapy*, R. Birngruber; H. Bergh; Eds., Proc. SPIE 4433, 180-185, 2001.
4. V.A. Privalov, I.V. Krochek, A.V. Lappa, "Osteoperforation with diode laser in treatment of acute and chronic osteomyelitis", *Bull. VSNT SO RAMN* **1, 3(17)**, 115-121, 2001. (in Russian)
5. V.A. Privalov, I.V. Krochek, A.V. Lappa, A.N.Poltavsky, A.N.Tkachov, "Laser osteoperforation in osteomyelitis treatment", in *Book of Abstracts*, 111, *8th International Congress EMLA, 1-st Russian congress of RMLA*, Moscow, 2001
6. V.A.Privalov, I.V.Krochek, A.V. Lappa, A.N. Poltavsky, "Method of surgical treatment of osteal and osteoarticular panaritium", Patent of Russian Federation №2235522 (Application date 10.09.2004).
7. V.A.Privalov, I.V.Krochek, A.V. Lappa, A.N. Poltavsky, "Method of treatment of chronic osteal and osteoarticular panaritium by laser osteoperforation" Patent of Russian Federation № 2209595 (Application date 15.05.2001).